


A retrospective panoramic study for alveolar bone loss among young adults in Sulaimani City, Iraq



Sulaimani Dental Journal

Faraedon M. Zardawi^{a*}, Alaa N. Aboud^b, Dler A. Khursheed^a

Abstract

Objective: to determine the prevalence of alveolar bone crest loss among a selected sample of archival orthopantomography (OPG) in relation to number of sites affected and gender in Sulaimani City.

Materials and methods: A retrospective study was conducted with an inclusive period running from March to December 2007 to determine the prevalence of alveolar bone loss among 1072 subjects on panoramic radiographs. Panoramic images were sampled at the radiological archive of Dental School Hospital–University of Sulaimani for a selected age class ranged from 17 to 30 years. Bone loss was estimated by measuring the distance from cemento-enamel junction (CEJ) minus 2 mm (physiologic high of interseptal alveolar crest) to the crest of the alveolar bone at sites with reduced normal level of interseptal bone. Total bone loss was divided into two groups according to number of sites affected; group one (1-3) sites showing bone loss per panoramic radiograph, and group 2 showing bone loss at more than 3 sites. Samples were also divided into two age groups; group one from 17 to 23 years and group two from 24 to 30 years. Moreover, bone loss was determined according to gender into male and female and number of sites affected for each gender.

Results: results showed that 347 images – 30.2% of the total images showed bone loss at one site or more. 14.6% of the images revealed bone loss at 1-3 sites, whereas, 15.6% demonstrated bone loss at more than 3 sites. Percentage of bone loss was significantly higher ($P=0.001$) among group two (24-30 years old group) than group one (17-23 years old group) 38% against 25% respectively. Female's radiographs recorded a non-significantly higher ($P>0.05$) bone loss than male's radiographs 31.7% against 28.7% respectively.

Conclusion: prevalence of bone loss among young adults in Sulaimani City was relatively high compared to other published reports. There was a predilection for female. Bone loss was more prevalent at (24-30 years old group) compared to (17-23 years old group).

Keywords: Orthopantomography, alveolar bone loss, aggressive periodontitis.

Received: September 2014, **Accepted:** November 2014.

Introduction:

Periodontitis is usually asymptomatic chronic inflammatory condition caused by bacterial aggregation which affects the crest of the alveolar process by reducing the normal height in a vertical and/or a horizontal manner; furthermore, bone loss might be presented in a localized or a generalized form⁽¹⁾. Bone destruction can be detected using several radiographical techniques that evaluate the quantity of the remaining bone and subsequently estimating the amount of bone loss on a radiograph. Panoramic radiography has a little diagnostic value in the identification of periodontal disease. It is useful as a general survey, but may not show precise details⁽²⁾. However, it can be used as a valuable adjunct to conventional diagnostic procedures. It can be recommended as a part of routine dental and periodontal assessment which captures the entire maxilla-mandibular radiographic image on a single film^(3,4). However, panoramic radiograph should not be used to replace other intraoral radiographies. Semenoff et al. (2011)⁽⁵⁾ assessed variations between different dental radiographs for assessment of the interseptal bone crest loss on conventional and

digitized periapical, bitewing, and panoramic radiographs. Comparison among them showed that a small reduction in height of interseptal bone crest observed in panoramic radiographs should be carefully evaluated for over estimation⁽⁵⁾. Moreover, several studies proposed that panoramic radiography might serve as a diagnostic aid in dental health evaluation programs^(4,6). Epidemiological studies from many countries employing different methods of criteria showed great variation in prevalence of early periodontitis in life⁽⁷⁾. It is acknowledged that early radiographic bone loss could be used as a screening method to identify subjects particularly susceptible to periodontitis⁽⁸⁾.

Searching online databases showed no radiographic screening records on the prevalence of bone loss among young and adult people in Kurdistan region. Therefore, the aim of this study was to conduct a radiographic screening in order to determine the prevalence of alveolar bone loss on digital panoramic records for patients their ages ranged between 17-30 years.

^a Department of Periodontology, School of Dentistry, University of Sulaimani, Iraq. *Corresponding author: dr_faraedon@yahoo.com

^b Department of Radiology, Shikh Omar Specialised Dental Center – Baghdad., Iraq.

Materials and methods:

Orthopantomography of 1072 subjects aged between 15 to 30 years were recruited from the records of the Department of Radiology at Dental School Hospital – University of Sulaimani from March to December 2007 in order to evaluate the interproximal alveolar bone loss and potential explanatory variables including age, gender and number of sites. Panoramic views were obtained using Planmeca 2002 CC Proline with Dimax3, Panoramic digital X-ray unit (60 KV and 20 mA), 1.2 magnification ratios. A digital method of estimating alveolar bone height on panoramic radiographs using 3X magnification was employed using constant anatomic landmarks as reference points - CEJ and alveolar crest. Bone loss considered when the distance from the CEJ to the alveolar crest exceeded 2 mm. Radiographic images were interpreted by one examiner - a dental radiologist in the department of radiology. Distorted, overlapped, unclear images particularly at the maxillary and mandibular anterior region or patients with orthodontic appliances were excluded in the study. Bone loss estimated digitally by measuring the distance between CEJ and alveolar crest at the interproximal areas minus 2 mm (physiologic high of interseptal alveolar crest) at sites with reduced normal level of interseptal bone^(9,10) as shown in Figure 1.

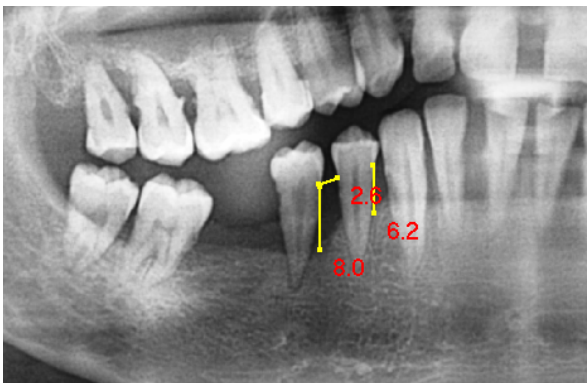


Figure 1: Estimation of the amount of bone loss digitally on the OPG image

The sample was divided into the following groups:

a- According to number of sites demarcated bone loss

Group one; radiographs revealing bone loss at 1- 3 sites

Group two; radiographs revealing bone loss at more than 3 sites

b- According to age groups

Group one; 17-23 years old group

Group two: 24-30 years old group

c- According to gender – male and female.

Ethical approval has been obtained from the University Research Ethics Committee, School of Dentistry – University of Sulaimani for the employing the panoramic radiography for conducting this study.

Descriptive statistics – tables, figures and percentages beside inferential statistics. Chi-square was used to present the results of the current study.

Results:

Table 1 demonstrates all recruited data including number of images showed bone loss and prevalence of bone loss according to age groups, number of sites affected per radiographic image and according to gender.

The height of interseptal bone was inspected on 1073 OPG images, 324 images (150 male and 174 female) revealed evidence of bone loss at one or more than one site, this record constitutes 30.2% of the total OPG images examined in this study, whereas, 748 images – 69.8% showed intact alveolar crests. 157 images showed bone loss at 1-3 sites per image, and 167 images showed bone loss at more than 3 sites per image statistically the difference between the two groups was non significant ($P > 0.05$).

Data analysed according to gender - male and female, 174 images (31.7%) panoramic images out of 549 for female showed bone loss at one or more sites, whereas 150 (28.7%) panoramic images out of 523 for male showed bone loss. Chi-square test revealed no significant ($P > 0.05$) difference between the two groups (Table 1).

In the current study OPG images were also interpreted according to age groups as shown in Table 1, the total OPG images included 633 images for age group one (17-23 years old), 158 images (25%) showed bone loss, whereas group two (24-30 years old) included 439 images, 166 images (37.8%) showed bone loss. Statistically the difference between the two age groups was highly significant ($P < 0.05$).

Table 2 shows that in age group one, 77 images (12.2%) had bone loss at 1-3 sites, whereas, 81 images (12.8%) revealed bone loss at more than 3 sites. The statistical analysis using chi square test shows non-significant difference of the prevalence of bone loss ($p > 0.05$) within the two different age groups in 1-3 sites.

Table 2 also shows that in age group two, 80 images (18.2%) had bone loss at 1-3 sites, whereas, 86 images (19.6%) showed more generalized pattern of bone loss (bone loss at more than 3 sites). The statistical analysis using chi square test showed non-significant difference of the prevalence of bone loss ($p > 0.05$) within the two different age groups in more than 3 sites.

Table 1: Prevalence of bone loss according to age and number of sites

Total		Affected		Not affected	
1072		324	30.2 %	748	69.8%

Group	Total	Affected	Chi square	P-value	
Gender	male	523	150 28.7%	X ² =0.62	P=0.43 NS
	female	549	174 31.7%		
Site	1-3	1072	157 14.6%	X ² =0.27	P=0.6 NS
	more than 3	1072	167 15.6%		
Age	17 – 23 y	633	158 25%	X ² =10.7	P=0.001 HS
	24-30 y	439	166 37.8%		

HS= high significant, NS= not significant

Table 2: Prevalence of bone loss according to age groups and number of sites affected

Age group	No. of site	Affected	Chi square	P-value
Age 17-23 y	1-3 sites	77 (12.2%)	X ² =0.09	P=0.76 NS
	More than 3 sites	81 (12.8%)		
Age 24-30 y	1-3 sites	80 (18.2%)	X ² =0.18	P=0.67 NS
	More than 3 sites	86 (19.6%)		

Discussion:

This retrospective study screened electronic radiographic images taken from the electronic archive of Department of Radiology at Teaching Hospital - School of Dentistry for presence or absence of interseptal bone loss exclusively and regardless of a thorough clinical examination for inspection of any local irritating factors, presence or absence of clinical signs of periodontitis and level of oral hygiene. Moreover, anatomical limitation⁽¹¹⁾ for interpreting OPG images i.e. lack of clarity for interpreting the interseptal bone at the maxillary and mandibular anterior regions and crowding teeth have an influence on the overall reliability and sensitivity of the method employed in this survey. Furthermore, this survey based on presence or absence of bone loss at one site and more as a diagnostic criterion. Therefore, the method used to interpret bone loss in this survey not necessarily indicates presence or absence of aggressive or chronic form of periodontitis since bone loss at 1-3 sites on a radiograph reveals intact interseptal bone

otherwise could be incidental to presence of a local factor at these sites such as calculus, open contacts or defective margins of restorations.

A consensus report of the 1999 workshop stated that an incidental attachment loss is an epidemiologic descriptor used for situations in which the clinical attachment loss cannot be attributed to the periodontal diseases such as aggressive or chronic periodontitis⁽¹²⁾. These cases usually referred to as incidental periodontitis rather than aggressive periodontitis⁽¹³⁾. However, such a lesion could be an initial stage or yet unrecognized stage of aggressive periodontitis especially when these initial lesions are detected at an early age of life. This study focused on the prevalence of bone loss in a limited population rather than focusing on the amount and extension of interproximal bone loss, furthermore the magnification ratio⁽¹⁴⁾ of a panoramic radiography may in turn constrain the interpreter to a wrong decision while estimating an early or a tiny lesion at the crest of the interseptal bone⁽¹¹⁾. Epidemiological investigations have reported

high prevalence of attachment and bone loss in adolescents and young adults does not fit the characteristic of recognized early onset periodontitis, such occurrence have been termed incidental attachment and bone loss, which has been reported to occur in 1.6-26% of subjects⁽¹⁵⁾.

Data obtained from the current panoramic survey showed high percentage of bone loss at the crest of the interseptal bone which involves 30% of the total radiographs examined, although half of the record comprises bone loss at less than 3 sites. However, the other half (15%) of the images examined showed bone loss at more than three sites, it is most likely that the majority of these cases are aggressive form of periodontitis presented in either localized or generalized form. Furthermore, results of the current study indicated a high prevalence of periodontitis among the sample examined. Higher incidence of bone loss in adult patients (24-30 years old) is a fact, that periodontitis is an age dependent disease the incidence and severity of bone loss and attachment loss increase with age⁽¹⁶⁾ as a result of longer exposure to local factors as age grows older. The present study revealed non significantly higher prevalence of bone loss among female than male, the outcome of this study is consistent with other studies stated a higher prevalence of aggressive periodontitis among females rather than males. Van der Veiden (1989) reported a female/male ratio of 1.3:1, the study conducted to determine the prevalence and clinical appearance of destructive periodontal disease in a school population of 15– to 16–year old adolescents in Amsterdam⁽¹⁷⁾. A higher prevalence of juvenile periodontitis in female against male was also reported by Hørsmann and Frandsen (1979)⁽¹⁸⁾. However, Susin and Albander (2005) recorded an equal distribution of aggressive periodontitis among male and female in an urban population in Southern Brazil⁽¹⁹⁾, whereas Albander et al 2002 reported a significantly higher prevalence of the disease in males than in females in school attendees in Uganda, aged between 15-25years⁽²⁰⁾. Variation in the prevalence of aggressive periodontitis and gender is attributed to the geographical and racial factors, furthermore, studies suggest differences between geographically and racially distinct populations in the prevalence of periodontopathic bacteria as well as greater periodontal destruction associated with infection by highly leucotoxic *Actinobacillus actinomycetemcomitans* (Aggregatibacter)⁽¹⁶⁾.

Radiographic images recruited in this study were not achieved exclusively for periodontal examination and diagnosis; they were achieved for different purposes in field of dentistry. Therefore, the significant of the current study is that a high prevalence of bone loss among young and adult has been recorded for our sample, which is considered as an alert sign for providing a suitable preventive and screening program among secondary students and graduated persons for early detection and prevention of primary periodontal

lesions. A screening program is required among our young and adults to identify subjects particularly susceptible to early periodontitis in life, hence involving the affected subjects into an early treatment schedule.

Conclusions:

Prevalence of bone loss among young persons in Sulaimani City was relatively high compared to other published reports with a predilection for female. Bone loss was significantly prevalent among adults compared to younger ages.

References:

1. Messier MD, Emde K, Stern L, Radhakrishnan J, Vernocchi L, Cheng B, et al. Radiographic periodontal bone loss in chronic kidney disease. *J Periodontol*. 2012;83:602-11.
2. Vijay G, Raghavan V. Radiology in periodontics. *J Indian Acad Oral Med Radiol*. 2013;25:24-29.
3. Salman A, Sabahat KA, Vikas D, Satish G. Radiology In periodontal disease diagnosis. *IJOMHS*. 2014;01:2-9.
4. Lee JS, Kang BC. Screening panoramic radiographs in a group of patients visiting a health promotion center. *Korean J Oral Maxillofac Radiol*. 2005;35:199–202.
5. Semenov L, Semenov TA, Pedro FL, Volpato ER, Machado MA, Borges AH, Semenov-Segundo A. Are panoramic radiographs reliable to diagnose mild alveolar bone resorption? *ISRN Dent*. 2011;2011:363578.
6. Osborne GE, Hemmings KW. A survey of disease changes observed on dental panoramic tomographs taken of patients attending a periodontology. *Clinic. Br Dent J*. 1992;173:166-8.
7. Lennon MA, Davies RM. Prevalence and distribution of alveolar bone loss in a population of 15-year-old school children. *J Clin Periodontol*. 1974;1:175-82,.
8. Albandar JM, Baghdady VS, Ghose LJ. Periodontal disease progression in teenagers with no preventive dental care provisions. *J Clin Periodontol*. 1991;18:300-4.
9. Hansen BF, Gjermo R, Bergwitz-Larsen KR. Periodontal bone loss in 15-year-old Norwegians. *J Clin Periodontol*. 1984;11:125-31.
10. Hansen BF, Gjermo P, Bellini HT, Ihanamaki K, Saxén L. Prevalence of radiographic alveolar bone loss in young adults, a multinational study. *Int Dent J*. 1995;45:54-61.
11. Ivanauskaitė D, Lindh C, Rangne K, Rohlin M. Comparison between Scanora panoramic radiography and bitewing radiography in the assessment of marginal bone tissue. *Stomatologija. Baltic Dent Maxillofac J*. 2006;8:9-15.
12. Wiebe CB, Putnins EE. The periodontal disease classification system of the American Academy of Periodontology—an update. *J Can Dent Assoc*. 2000;66:594-7.
13. Albandar JM, Tinoco EMB. Global epidemiology of periodontal disease in children and young persons. *Periodontol* 2000. 2002;29:153-76.

14. Chiles JL, Gores RJ. Anatomic interpretation of the orthopantomogram. *Oral Surg Oral Med Oral Pathol.* 1973;35:564-74.
15. Lindhe J, Lang NP, Karring T. *Clinical periodontology and implant dentistry*, 5th edition. UK: Wiley-Blackwell; 2008.
16. Cortelli JR, Cortelli SC, Jordan S, Haraszthy VI, Zambon JJ. Prevalence of periodontal pathogens in Brazilians with aggressive or chronic periodontitis. *J Clin Periodontol.* 2005; 32:860-6.
17. van der Velden U, Abbas F, van Steenberghe TJM, De Zoete OJ, Hesse M, De Ruyter, et al. Prevalence of periodontal breakdown in adolescents and presence of *Actinobacillus actinomycetemcomitans* in subjects with attachment loss. *J Periodontol.* 1989; 60:604-10.
18. Høsrmand J, Frandsen A. Juvenile periodontitis localization of bone loss in relation to age, sex, and teeth. *J Clin Periodontol.* 1979;6:407-16.
19. Susin C, Albandar JM. Aggressive periodontitis in an urban population in southern Brazil. *J periodontol.* 2005;76:468-75.
20. Albandar JM, Muranga MB, Rams TE. Prevalence of aggressive periodontitis in school attendees in Uganda. *J Clin Periodontol.* 2002;29:823-31.